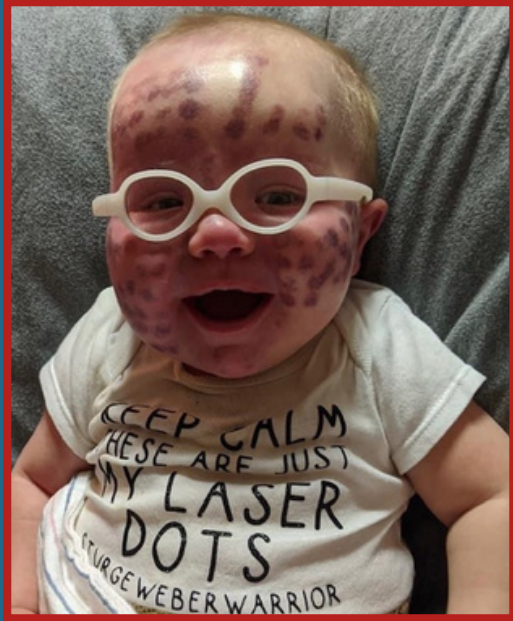



ASLMS/VBF Laser Treatment Best Practices for Vascular Birthmarks

Paul M. Friedman, MD

Director of Dermatology & Laser Surgery Center, 2022 VBF Physician of the Year, 2022-2023 ASLMS President

Linda Rozell-Shannon, PhD

President and Founder of the Vascular Birthmarks Foundation (VBF)

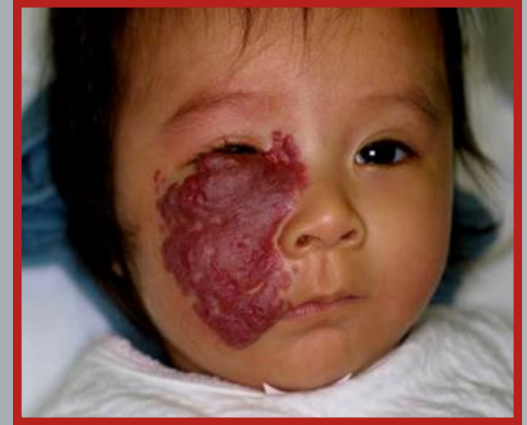It is advisable that the laser treatment of a cutaneous vascular birthmark be initiated as soon as it has been deemed safe to proceed.



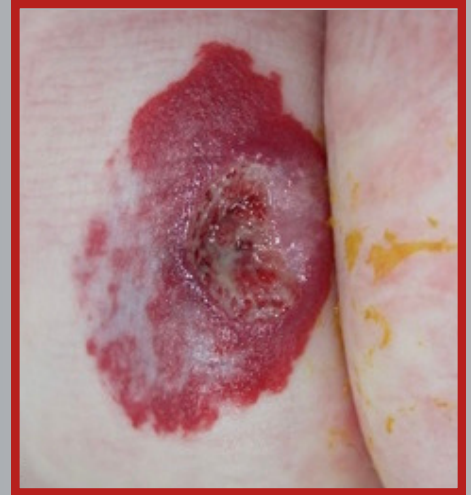It is advisable that diagnosis of cutaneous vascular birthmarks be based upon presentation during the neonatal period. There are some exceptions with cutaneous vascular birthmarks that present beyond infancy, which should be further explored prior to initiating laser treatment.



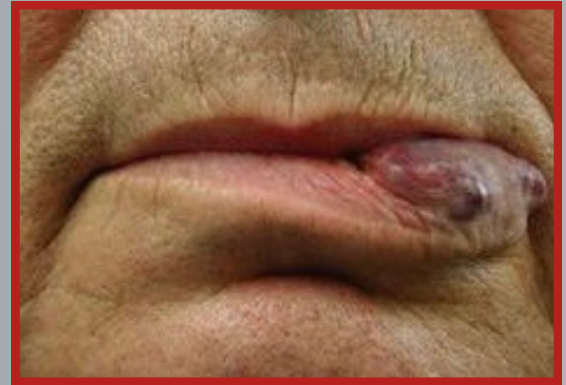It is advisable that if there is uncertainty as to the type of lesion, further studies and routine examinations should be made until diagnosis can be confirmed.



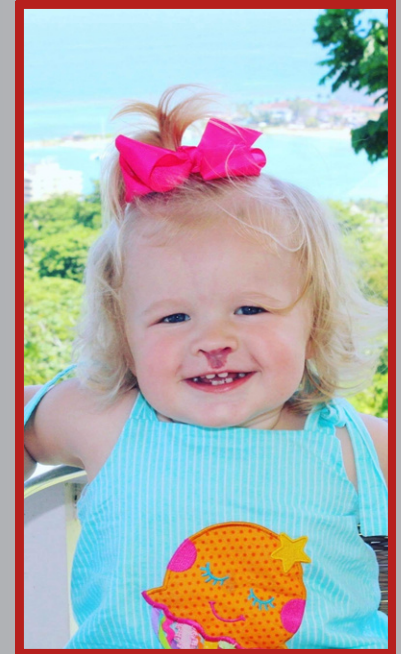
It is advisable that if a vascular birthmark has been ulcerated, burned, or damaged from a laser treatment, allow time for tissue to heal before resuming treatment. If it is an Infantile Hemangioma and it is ulcerated, sometimes the laser can be beneficial if done with proper settings and with caution.



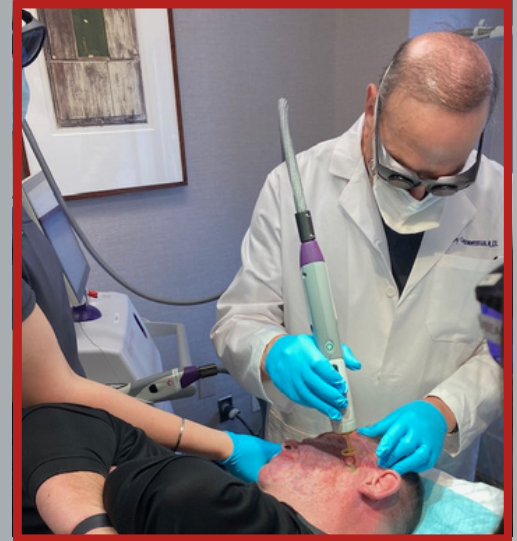
Some lesions thicker than 4mm may not respond to typical pulse dye laser but may respond to other lasers and/or other medical or surgical modalities, such as the NdYag. Further clearance may be acquired with combining lasers and/or with some special techniques used to enhance treatment depth.



It is advisable that cutaneous lesions with a pronounced bruit or reported to have a “pulse” should be investigated to rule out high flow lesions.



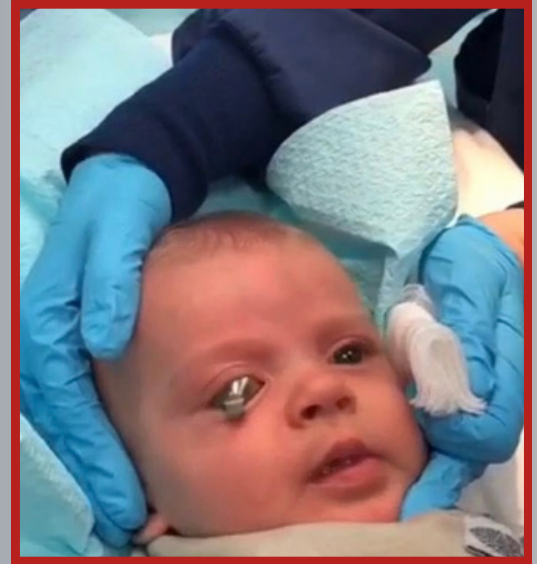As of 2022, the Pulse Dye Laser is considered the gold standard for treating vascular birthmarks.



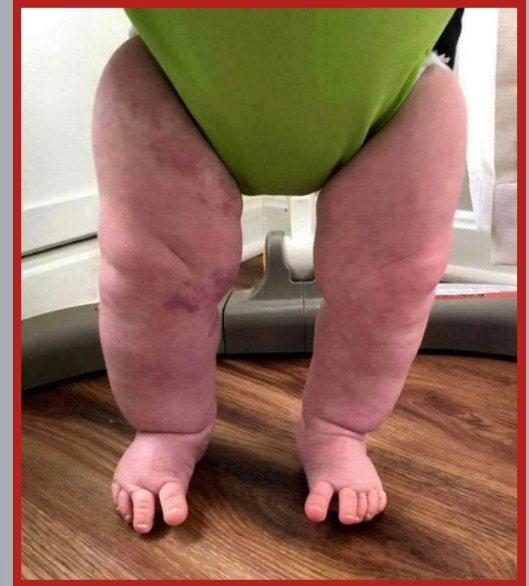
It is advisable that patients with a vascular birthmark around the temple, forehead, orbit, and eyelids should be referred for evaluation of Sturge Weber Syndrome (SWS). Laser can be done, but it is advisable that a referral for investigation of the orbit or meningeal involvement should be prescribed and patients should be informed of the possible co-morbidity. Referral to a glaucoma expert and/or neurologist should be considered to rule out SWS.



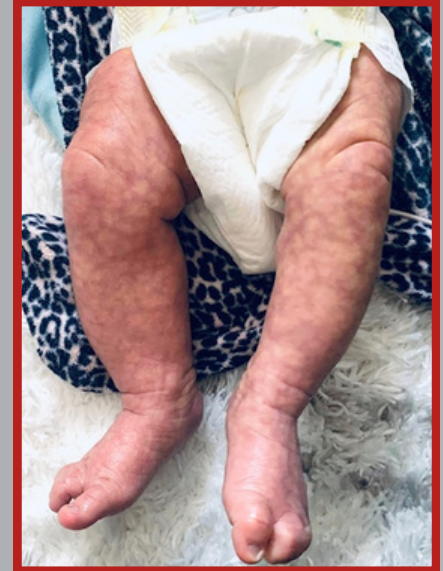It is advisable that any patient that has a vascular birthmark around the eyelid area should be lasered after metal eye shields have been properly inserted.



It is advisable that patients with a vascular birthmark on the extremities, or torso, which presents with a discrepancy in size from the opposite, non-birthmarked side, should be referred for imaging to rule out any associated syndrome (such as KTS or CMTC). In some instances, these can be lasered, however, extremity lesions do not usually have a high response. When discussing lasering these extremity lesions, the earlier age the treatment begins, the better the response.



It is advisable that patients with a marbling appearance of a vascular birthmark should be investigated for CMTC (Cutis Marmorata Telangiectatica Congenita). Lasering may be done, but since these often fade, consideration should be given to waiting to see if it begins to fade, but also with a referral for neurological evaluation.



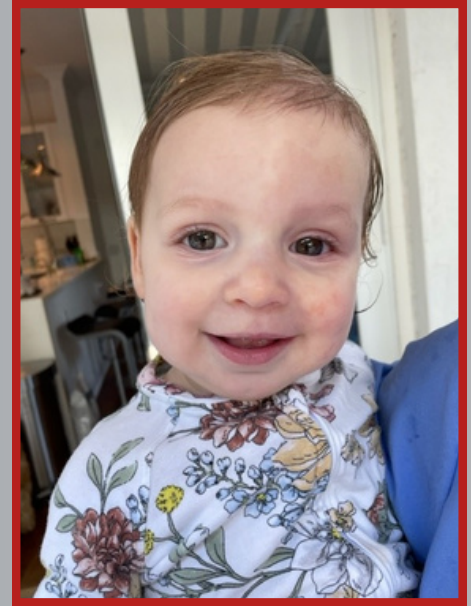It is advisable that patients who present with dental asymmetry, when a stain is present on the gums, should be referred for imaging and for a dental exam.



It is advisable that after modulating settings, and even after trying various devices, if there is no subsequent improvement in 3 consecutive treatments, discuss with family the option to discontinue treatment for a period of time, and/or consider seeking a second opinion.



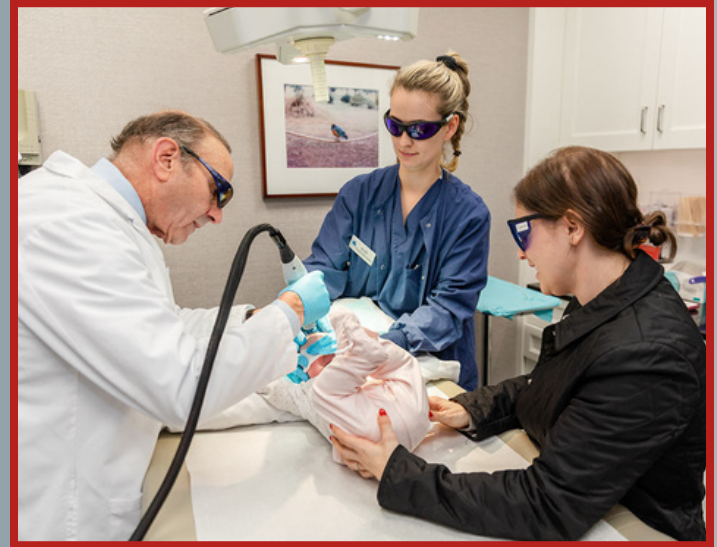Maximum clearance is a subjective term that needs to be mutually agreed upon between clinician and the patient and/or caregiver. Some patients want some clearance and some want all clearance. Sometimes “all” clearance cannot be achieved. It is important to know when a particular lesion has reached its maximum clearance potential. It is advisable that this “max point” should be evaluated periodically with the patient so as to prevent false expectations.



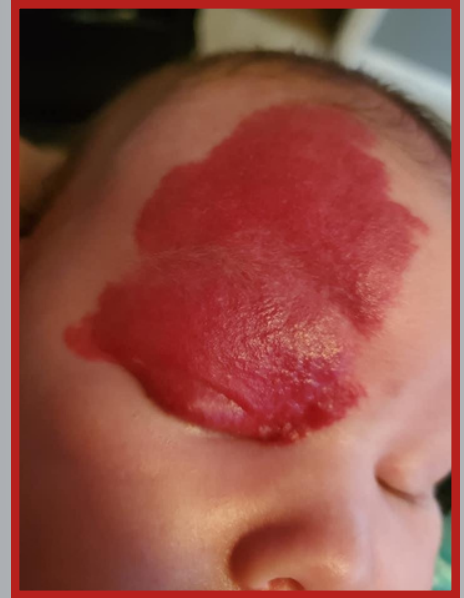It is advisable that the Fitzpatrick Skin Type Scale should be considered, as well as skin thickness and birthmark density, to determine laser settings and selection.



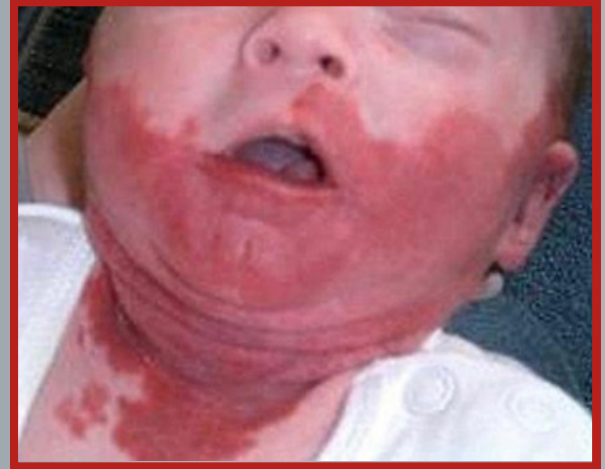It is advisable that the pros and cons of general anesthesia versus other anesthesia/non anesthesia pain management options should be discussed with patient and a mutually agreed upon decision reached between clinician and patient.



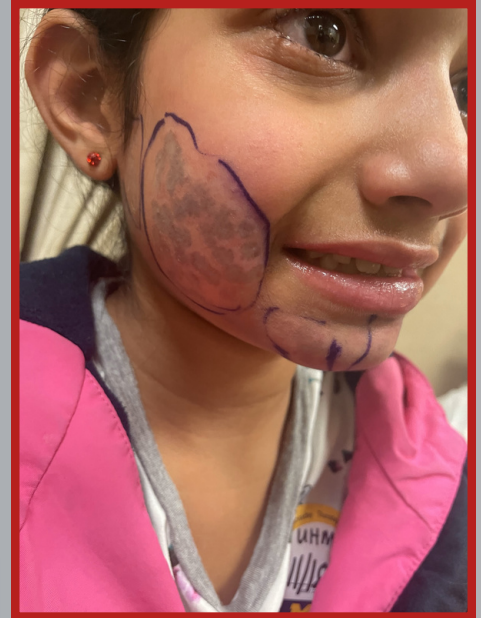There is no sure way to determine if a flat red macule is a port wine stain or an infantile hemangioma since both can appear flat and blanch. It is advisable that, if uncertain, see the patient back any time after 2 weeks and it should be evident which one it is so that treatment can coincide with birthmark type. This uncertainty should not prevent initiating laser treatment.



Large segmental early emerging Infantile Hemangiomas can be treated with a laser. However, since some may ulcerate, it is advisable to consider either doing a test spot or laser in sections to determine if you can safely proceed, or consider combining with medical therapy. If all is well, the entire hemangioma can be treated. These segmental hemangiomas should be investigated for PHACES Syndrome.



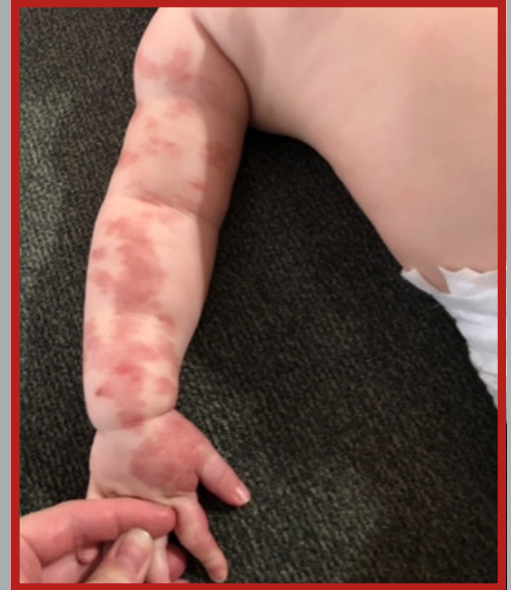It is optional, but it is often helpful, for the birthmark to be outlined prior to lasering. Whatever pen is used to outline the birthmark, it should be investigated to insure there are no flammable ingredients.



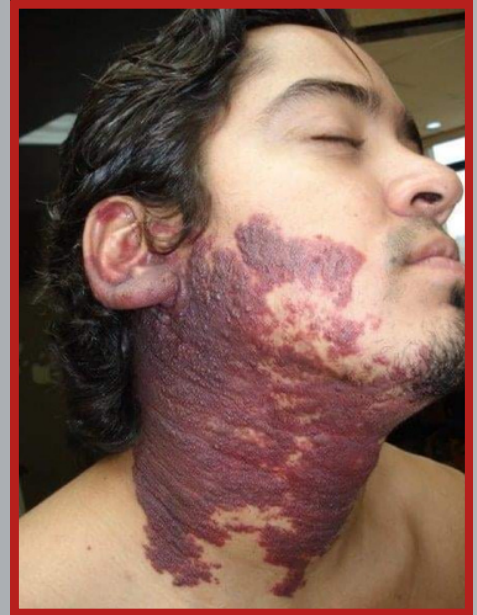It is advisable that non-pharmacologic agents and analgesics should be considered as alternatives to General Anesthesia. These include ice/heat, pacifiers, breastfeeding, buzzy (vibrating device), parent comfort, bubbles or pinwheels, swaddling, videos/music or the services of a Child Life Specialist. SweetUms (a 24% sucralose solution) has been used effectively in brief medical procedures to provide a small burst of comfort for the infant. These options should be considered for treating patients under age 16.



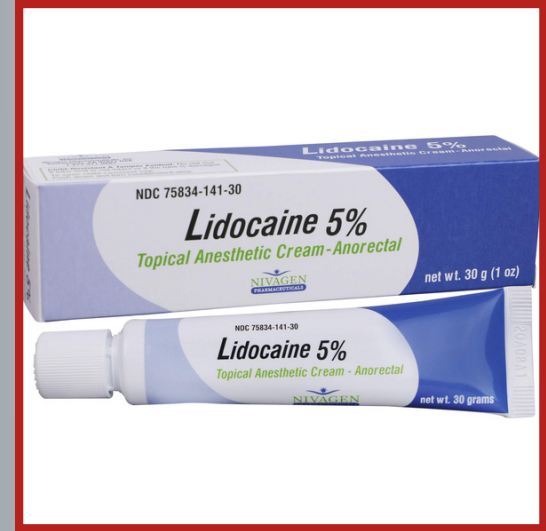Pharmacologic analgesics should be explored, especially for extensive birthmark treatment in pediatrics.



There are multiple approaches to lasering large segmental port wine stains. This can include breaking down the lesion into segments and using non GA for pain management versus using GA and lasering the entire lesion. It is advisable that options and pros and cons of each approach should be discussed with the patient and/or parent.



Topicals that are used in most hospitals for punctures, such as lidocaine, lidocaine with prilocaine, lidocaine with epinephrine, and tetracaine, should be used with caution in an office setting to treat larger vascular birthmarks in pediatrics. Consideration should be given to the amount applied to the skin surface vs. the surface area size.



It is advisable that opioids should never be used in pediatric patients being treated by laser for a vascular birthmark.



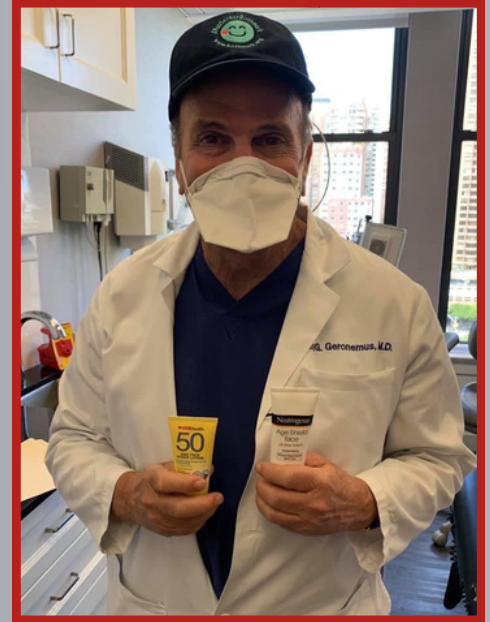
It is advisable that post laser treatment instructions may include the use of ice or cool compress.



Heavy emollients or barrier creams such as Aquaphor or Vaseline may be used as needed post laser procedure.



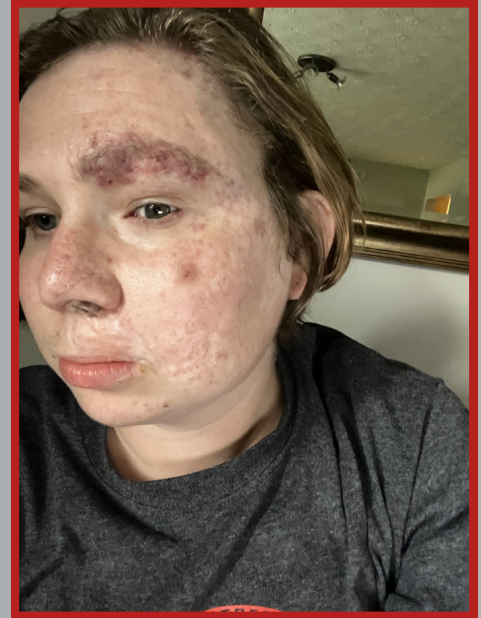It is advisable that sunscreen should always be used following all laser treatments. Wearing a hat and avoiding the sun for up to 10 weeks following treatment is recommended.



While purpura is typically a desired treatment endpoint, it does not necessarily equate to clinic effectiveness, especially in newborns where there is often no purpuric response.



In some instances, purpura may not be apparent. This may be due to skin pigmentation and age of the patient.



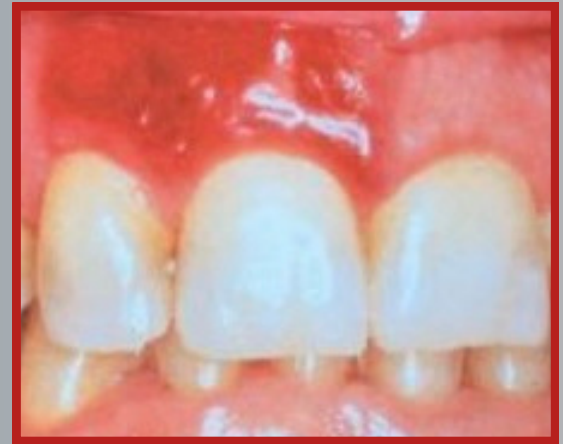It is advisable that both pediatric and adult patients who seem to exhibit extreme anxiousness, anxiety, or nervousness before, during, and/or after treatment may be referred for psychosocial support.



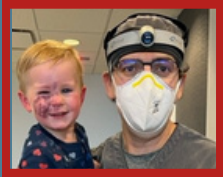It is advisable that laser experts should avoid using the word “cure” for treating vascular birthmarks. Preference should be to “improve” the lesion. Hemangiomas can be cured, but a port wine stain can be improved, not cured.



It is advisable that consideration for treating the gums of patients with hyper vascular gums associated with a port wine stain should be given to laser type and expertise of clinician. Since the use of a vascular laser on gums can result in an infarct to the blood supply of the tooth, it should not be used. Other lasers can be considered for the gums. Consultation with a dental expert should be considered.



About the Authors



Paul M. Friedman, MD

Director of Dermatology & Laser Surgery Center
2022 VBF Physician of the Year
2022-2023 ASLMS President



Linda Rozell-Shannon, PhD

President and Founder of the Vascular Birthmarks Foundation (VBF)

Consensus Team

Sami Alsuwaidan, MD
R. Rox Anderson, MD
Vivian Banh, DO
Branko Bojovic, MD
Candela Medical
Henry Hin Lee Chan, MD

Bernard Cohen, MD
Sherry Cohen, NP
Giacomo Colletti, MD, DDS
Anne Comi, MD
Scott Cupples
Kami Delfanian, MD

Roy Geronemus, MD
Gerald Goldberg, MD
Barb Humphreys, RN
Jerome Garden, MD
Leslie Graff, MS, CCLS
Taro Kono, MD

Paul LeGrice, MD
J. Stuart Nelson, MD
Carsten Philipp, MD
Pooja Sodha, MD
Wenbin Tan, PhD
Zeina Tannous, MD

